



PATIENT

Jersey Maclean

SPECIES

Canine

BREED

Chihuahua

SEX

Male Neutered

AGE

11 years

WEIGHT

10.4lbs

INTERPRETED BY

Maggie Machen Lamy,
DVM, DACVIM
(Cardiology)

IMAGING PERFORMED BY

S. Barthelemy, DVM

HOSPITAL NAME

Falconridge Animal
Hospital

REFERRING VET

Dr. Rix

INVOICE

28073

DATE

1/3/23

PRESENTING CLINICAL SIGNS

History: New grade 5/6 heart murmur. Asymptomatic.

ECHOCARDIOGRAM FINDINGS

2D, m-mode, color flow and doppler imaging is available. Diffuse thickening of mitral valve leaflets with minimal prolapse into the left atrial lumen. Moderate eccentric mitral regurgitation with mild left atrial dilation. Elevated MR velocity. Normal LV diameter with adequate myocardial function. The tricuspid valve appears normal with no tricuspid regurgitation. Normal right atrial and ventricular diameter and morphology indicating no overt evidence of pulmonary arterial hypertension. The pulmonic and aortic valves are normal in morphology and mobility. Normal pulmonic and aortic outflow velocities with laminar flow. No obvious aortic or pulmonic insufficiency. No pericardial or pleural effusion noted. No obvious cardiac masses.

CARDIAC CHART

CANINE CARDIAC PARAMETERS	MR VMAX (m/s)	TR VMAX (m/s)	LA/AO (Boon method)	LA/AO (Heart Base; Swe)	FS (%)	EF (%)	EPSS (cm)
NORMAL PARAMETER	4.5-5.5	<2.7	1.3	<1.6	28-40	40-100	<0.6
PATIENT	6.3	NA	1.6	1.55	60	91	0.2
CANINE CARDIAC PARAMETERS	HR (BPM)	AV VMAX (m/s)	PV MAX (m/s)	BODY WEIGHT (kg)	LA 2D short axis Base view (cm)	LVIDd Avg; 2D and m-mode short axis (cm)	LVIDs Avg; 2D and m-mode short axis (cm)
NORMAL PARAMETER	50-100	0.7-1.7	0.7-1.6	BELOW	BELOW	BELOW	BELOW
PATIENT	160	1.0	0.5	4.7	1.9	2.6	1.1
*Normal chamber parameters expressed as a mean value (SD)				3	1.27 (5.3)	2.46 (2.46)	1.36 (5.5)
BODY WEIGHT DEPENDENT PARAMETERS				5	1.40 (4.5)	2.74 (5.2)	1.60 (4.7)
<i>*Note: All measurements based upon multi-modal images and methods. An average value is reported.</i>				10	1.50 (3.8)	3.27 (3.5)	2.06 (3.1)
				15	1.83 (2.0)	3.71 (2.4)	2.43 (2.1)
				20	2.02 (1.9)	4.14 (2.2)	2.80 (2.0)
				25	2.18 (2.4)	4.48 (2.9)	3.10 (2.5)
				30	2.33 (3.3)	4.83 (3.9)	3.39 (3.4)
				35	2.48 (4.3)	5.17 (5.0)	3.69 (4.5)
				40	2.62 (5.2)	5.48 (6.1)	3.96 (5.4)
				50	2.88 (7.1)	6.07 (8.3)	4.46 (7.4)

Adapted from June Boon, Veterinary Echocardiography, 1998
Rishniw M and Hollis NE, J Vet Intern Med 2000; 14:429-435
Hansson et al, Vet Rad and Ultrasound 2002
Bonagura et al. Echocardiography: principles of interpretation, Vet Clin North Am 15:1177, 1995

INTERPRETATION OF THE FINDINGS & FURTHER RECOMMENDATIONS

Chronic degenerative valve disease causing moderate mitral regurgitation. Lack of significant left atrial enlargement indicates the current risk for complication is low. An elevated MR velocity is noted, and a baseline blood pressure is recommended. No concurrent issues such as systolic dysfunction or pulmonary hypertension are noted in this study.

In an asymptomatic dog with no significant left atrial enlargement, no cardiac medications are clearly indicated. Assessment of progression in the future will help predict long term prognosis, which is highly variable at this stage (B1). Omega fatty acid supplementation and mild salt restriction may be of some long-term benefit. Monitor for development of a cough, labored breathing, exercise intolerance or collapse episodes.



PATIENT

Jersey Maclean

SPECIES

Canine

BREED

Chihuahua

SEX

Male Neutered

AGE

11 years

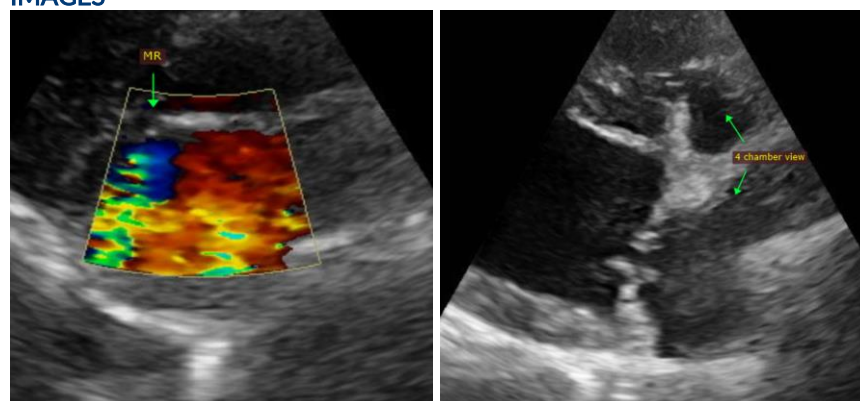
WEIGHT

10.4lbs

Anesthetic risk is considered mild if needed. Cardiac protective drug choices (opioid/benzodiazepine premedication, propofol or alfaxalone induction, isoflurane gas) are recommended. Pre-oxygenate for 5-10 minutes prior to induction. Monitor for arrhythmias, hypotension, and hypoxia both intra and post-operatively and intervene as necessary. Mild IV fluid restriction is recommended to avoid fluid overload. Avoid heart rate stimulating drugs such as atropine unless clinically indicated.

Recommend conservative monitoring with a recheck echocardiogram in 6 months, sooner if any development of clinical signs.

IMAGES



INTERPRETED BY

Maggie Machen Lamy,
DVM, DACVIM
(Cardiology)

The information and recommendations provided are based on the images presented by the referring veterinarian. No evaluation can be communicated regarding pathology that was not visible in the image/video clips provided.

Thank you for this referral. This report was generated using transcription software, and minor dictation errors may be present. If the clinical or image interpretation does not parallel your findings or if I can be of any further assistance, please contact me.

IMAGING PERFORMED BY

S. Barthelemy, DVM

Maggie Machen Lamy, DVM
Diplomate of the American College of Veterinary Internal Medicine (Cardiology)
info@sonopath.com

HOSPITAL NAME

Falconridge Animal
Hospital

REFERRING VET

Dr. Rix

INVOICE

28073

DATE

1/3/23